

The Role of Microfat Grafting in Facial Contouring

Nicole Lindenblatt, MD; Astrid van Hulle; Alexis M. Verpaele, MD; and Patrick L. Tonnard, MD

Aesthetic Surgery Journal
2015, Vol 35(7) 763–771
© 2015 The American Society for
Aesthetic Plastic Surgery, Inc.
Reprints and permission:
journals.permissions@oup.com
DOI: 10.1093/asj/sjv083
www.aestheticsurgeryjournal.com

OXFORD
UNIVERSITY PRESS

Abstract

Background: Congenital hypoplasia of facial bones has traditionally been treated by orthognathic surgery. However, the inherent invasiveness of orthognathic surgery often leads to a high complication rate. Facial fat grafting could be a less invasive method to correct facial deformities.

Objectives: The aim of this study was to evaluate the results of microfat grafting for facial contouring.

Methods: This retrospective chart review evaluated 166 patients who were treated with microfat grafting for maxillary and/or mandibular hypoplasia. Pretreatment and posttreatment photographs were compared regarding improvement of facial contour, and complications were recorded.

Results: The follow-up period ranged from 4 months to 10 years (mean, 2 years 7 months). Thirty-eight percent of the patients had a refill procedure 6 or more months after the first procedure. A majority of the evaluated patients stated that they benefited from the microfat grafting, with ratings of excellent (50%), sufficient (48%), and poor (2%). Complications included visible fat lobules under the lower eyelid skin (7%), which was seen during the first 4 years and was resolved by changing the injection cannulae and technique, and fat resorption, which was seen in all patients, with a clinical range from $\pm 15\%$ in the immobile malar area and chin region to $\pm 50\%$ in the mobile lip area.

Conclusions: Facial microfat grafting is a valuable alternative to more complicated advancement osetotomies being performed in patients solely for aesthetic reasons. The low morbidity and rapid recovery make facial microfat grafting a welcome tool in the armamentarium of the modern facial aesthetic surgeon.

Level of Evidence: 4



Accepted for publication April 16, 2015.

The 3-dimensional (3D) appearance of the human face is mainly based on two structures, the bony framework of the skull and the soft-tissue cover, the latter of which is composed of muscles, glands, and to a varying degree, fat. Congenital hypoplasia of the facial structures may be based on either osseous underdevelopment or deletion, for example, maxillary and mandibular hypoplasia, cranial clefts and syndromes such as Treacher Collins syndrome, or atrophies of the soft tissues as seen in Parry-Romberg syndrome.¹⁻³ Hypoplasia of bony structures has traditionally been treated through orthognathic surgery, which corrects the underlying osseous cause of the visible facial volume deficit.⁴ However, the rate of complications is high for this invasiveness type of orthognathic surgery.⁵ Such complications include hemorrhage, infection, nerve damage,

temporomandibular joint problems, malocclusion, bone necrosis, failure of osteosynthesis material, and death⁶⁻¹⁰ (Table 1). In addition, patients inevitably face a long recovery period.

Prof Lindenblatt is a Senior Attending Plastic Surgeon, Division of Plastic and Reconstructive Surgery, University Hospital Zurich, Zurich, Switzerland. Ms Van Hulle is a plastic surgery resident at a private practice in Gent, Belgium. Drs Verpaele and Tonnard are plastic surgeons in private practice in Gent, Belgium.

Corresponding Author:

Prof Nicole Lindenblatt, Division of Plastic and Reconstructive Surgery, Department of Surgery, University Hospital Zurich, Raemistrasse 100, 8091 Zurich, Switzerland.
E-mail: niclindenblatt@hotmail.com

Table 1. Complications After Orthognathic Surgery

Complication	Incidence
Hemorrhage ^{5,10}	2.0%-29.0%
Infection ⁹	9.0%-28.0%
Damaged inferior alveolar nerve ¹¹⁻¹³	8.3%-48.0%
Mandibular nerve sensory deficit ⁹	2.0%-17.0%
Material fracture ⁵	10.0%-23.0%
Temporomandibular joint disorders ⁵	11.0%
Maxillary sinusitis ¹⁴	4.8%
Blindness ¹⁵	NA ^a
Aseptic necrosis of maxilla ¹⁶	NA ^b
Combined damage of CN II, VI, V ₁ , and V ₂ ⁶	NA ^c

CN, Cranial nerve. ^a8 patients. ^b36 patients. ^cCase report.

Facial fat grafting to address age-related volume loss, soften facial wrinkles, and improve skin texture has become popular over the past decade.¹⁷⁻²¹ Autologous fat is a biological and durable filler material that can easily be harvested with low donor-site morbidity in most patients. Indications for fat grafting have recently been expanded, and fat grafting has also been used to treat acquired facial atrophies of different etiologies.^{22,23}

Severe cases of malnutrition, speech or breathing problems, or severe jaw deformity cannot be corrected through orthodontic treatment alone.²⁴ Moreover, because redirection of tooth growth is impossible in adults, orthognathic surgery is often required to correct severe open bite.²⁵ However, in patients with mild maxillary or mandibular hypoplasia, occlusion problems of the teeth occur infrequently and can usually be corrected in childhood or later, during adult life, through orthodontic treatment.²⁵⁻²⁹ Therefore, the main purpose of orthognathic surgery is purely aesthetic correction of the facial proportions.^{4,30}

In this study we analyzed 166 patients in whom facial disproportions due to mild to moderate maxillary and/or mandibular hypoplasia were successfully improved through autologous microfat grafting, thus avoiding invasive orthognathic surgery.

METHODS

Study Design

We evaluated data on 166 patients who were treated between October 2004 and October 2014 with microfat grafting for maxillary and/or mandibular hypoplasia, with the intent of the two senior authors (P.L.T. and A.M.V.) to

analyze the augmentation of facial volume in a retrospective fashion. Pretreatment and posttreatment photographs in 3 views (frontal, oblique, and profile) were compared regarding the improvement in facial contour and symmetry, and complications were recorded. Informed consent was provided by all patients.

The indication for facial contouring was provided when a patient wanted to actually change the facial appearance and proportions rather than merely having a rejuvenating procedure, which differs because it attempts to make the patient's face look younger. The inclusion criterion was a request to change the facial features (eg, through chin augmentation, malar augmentation, or midface augmentation). The exclusion criteria were cases of severe open bite, malnutrition, speech or breathing problems, or other severe jaw deformities that could not be corrected through orthodontic treatment alone.

Microfat Grafting Technique

Procedures were performed under general or local anesthesia, and all patients were given an antibiotic (cefazolin 1000 mg IV under general anesthesia plus amoxicillin 4 × 500 mg orally for 2 days versus amoxicillin 4 × 500 mg orally for 3 days under local anesthesia). The preferred donor sites were the abdomen (123 cases, 74%), hips (38 cases, 23%), knees (3 cases, 2%), and anterior thigh (2 cases, 1%), each of which was marked pretreatment with the patient standing. Other donor sites were the saddlebags or the inside of the thigh or knee.

Fat harvesting and preparation were performed.^{2,3} Klein's solution with 800 mg of lidocaine with adrenaline (1:1,000,000) was infiltrated in the donor sites through a 2 mm stab incision along the skin tension. Liposuction was performed with a 2 or 3 mm diameter cannula with multiple, sharpened 1 mm holes (Tulip Medical, San Diego, CA).

Because more liquid is aspirated with a fine, multiholed cannulae rather than the larger single-holed cannula we used a multiholed cannula to obtain a total aspirate volume of approximately 5 times the estimated fat volume to be injected in the facial areas. The liposuction harvest is then poured over a sterile nylon cloth with 0.5 mm perforations mounted over a sterile canister. The fat is rinsed with saline and transferred into 1 mL syringes. Blunt 0.7 mm diameter microcannulae with a single hole at the end (Tulip Medical, San Diego, CA) were used to inject the fat into the face. The microcannulae were introduced through a puncture hole made with a 19-gauge needle.

The areas to be injected were marked pretreatment with the patient in a sitting position. For maxillary hypoplasia, the malar region and the upper lip were treated. Fat deposition in the malar area was carried out as deep as possible on the malar bone. When the upper lip was injected to augment the anterior projection, the whole thickness of the

upper lip was injected 3-dimensionally from one nasolabial fold to the other, from the nasal base to the vermilion border, and from the oral mucosa to the lip skin. In patients with mandibular hypoplasia, the treatment areas included the mandibular ramus and the chin as well as the lower part of the lower lip. After marking the recipient areas, we infiltrated them with a lidocaine/adrenaline solution (0.3% lidocaine with adrenaline 1:600,000) in a subcutaneous plane. For malar augmentation, the microcannulae were inserted and the injected volume of the microfat was deposited through the typical multistroke Coleman technique in a layer deep to the orbicularis oculi muscle in contact with the zygomatic bone. In mandibular augmentation, the microfat grafts are deposited along the mandibular bone in the chin area, blending into the lower lip.

Injected volumes of microfat ranged from 8 to 25 mL (mean, 13 mL) per side for the malar areas, from 8 to 17 mL (mean, 12 mL) for the upper lip, and from 12 to 27 mL (mean, 15 mL) for the chin area. Of the 166 patients, 96 were treated to augment the malar region (58%), 35 patients had a combined malar and upper lip augmentation (21%), 24 were treated to augment the chin area (14%), and 11 were treated to augment the anterior projection of the lip region (7%). All patients were informed that a certain resorption of the fat volume will take place and that a second procedure could be necessary to obtain the desired result.

A refill procedure was performed on 63 patients (38%) 6 or more months after the first procedure (range, 6 to 89 months; mean, 8.3 months) because the surgeon and/or the patients considered the augmentation result inadequate. Five other patients (3%) had a third session of fat injection. All refill procedures were performed under local anesthesia, with the exception of 3 patients who underwent other aesthetic procedures requiring general anesthesia (2 breast augmentations and 1 abdominoplasty). Among the 68 patients who underwent a second or a third filling procedure, 44 were treated on their own request and the remaining 24 patients were treated per our request, with no patients refusing the touch-up procedure.

RESULTS

Among the 178 patients included in this retrospective chart review, 12 patients were lost from follow-up and 166 remained traceable, of which 148 patients were seen polyclinically and had posttreatment photographs taken. All patients stated that they benefited from the treatment(s) performed. The remaining 18 traceable patients were not able to consult physically and were interviewed on the telephone or by Skype consultation. These patients were asked to take and provide posttreatment photographs of themselves.

One hundred twelve patients were female (67%) and 54 were male (33%). The age of the patients ranged from

17 to 66 years (mean, 42 years). Most cases of microfat grafting for facial contouring (92%) were combined with other aesthetic procedures such as facelift (103 cases, 62%), rhinoplasty (43 cases, 26%), and blepharoplasty (6 cases, 4%). Twelve cases (7%) were isolated augmentations of the facial skeleton. Follow-up ranged from 4 months to 10 years (mean, 2 years and 7 months).

Results were clinically evaluated and the photographs were evaluated by the 2 operating surgeons and the patients and classified as either excellent, sufficient, or poor. A first analysis was performed in May 2010, and the results were classified as part excellent in 28 cases (17%), sufficient in 113 cases (68%), and poor in 25 cases (15%). After refill treatment of the poor-result cases and some of the sufficient-result cases (15 patients), a second analysis in October 2014 revealed the following classification for the cases: excellent (50%), sufficient (48%), and poor (2%). The increased satisfaction rate most likely is due to an improvement of the result over time.

The posttreatment period for all traceable patients was marked by a period of physical disfigurement resulting in incapacity from work or school that lasted between 8 and 45 days (mean, 24 days). This was influenced by concomitant surgery such as rhinoplasty, minimal-access cranial suspension (MACS) lift, or blepharoplasty.

The only complication noted was visible fat lobules under the lower eyelid skin in 12 cases (7%). The fat lobules were seen during the first 4 years and were resolved by changing the injection cannulae to 1 mm multiholed cannulae and by changing the injection technique to avoid excessively superficial fat deposition under the lower eyelid skin.

Fat resorption was seen in all patients and ranged clinically from $\pm 15\%$ in the immobile malar area and chin region to $\pm 50\%$ in the mobile lip area. Fat resorption rates were measured clinically through comparison with the pretreatment photographs. As previously mentioned, a second or third fat filling procedure was proposed to some of the patients. Two patients had exaggerated projection of the treated area (1 to the malar area and 1 to the chin area) after substantial weight gain. A local anesthetic was used before we performed meticulous liposuction of the hyperfilled area with a 2 mm Mercedes cannula, which corrected these problems.

DISCUSSION

The impression of facial beauty relies largely on symmetry and balanced proportions. Although the eyes and the lips are typically the most striking facial elements, the appearance of the middle and lower thirds of the face and their relationship to each other play a pivotal role in creating harmony. This is particularly true when the face is viewed laterally; that is, in profile, when disproportions in the relationship between the maxilla and the mandible become more evident. Fattahi³¹ reported that corrective jaw surgery

has brought about the possibility to move and alter the dentofacial skeleton to improve occlusion, function, and aesthetics. Even though the altered position of specific bony structures can be planned quite reliably in orthognathic surgery, the final 3D soft-tissue profile overlying this framework may be difficult to predict.

According to Patel and Novia,³² the most common procedures to address facial hypoplasia are the Le Fort I osteotomy for maxillary hypoplasia and the bilateral sagittal split osteotomy (BSSO) with or without genioplasty for mandibular hypoplasia. The most commonly performed genioplastic procedure is chin augmentation, which can be achieved through sliding genioplasty or implant placement. Peppersack and Chausse³³ stated that BSSO represents the standard procedure for mandibular advancement. The risk for mental nerve injury in genioplasty alone has been described to be as high as 10%.³⁴ In a series of 50 patients, Gianni et al⁷ reported chin hypesthesia in 17% of the patients in genioplasty alone and in 40% of the patients who underwent BSSO and genioplasty together. Lindquist and Obeid³⁴ even described an abnormal feeling of the lower lip in 71% of patients after BSSO. In a study of 172 patients, Mensick et al¹¹ stated that injury to the inferior alveolar nerve was found in 29% of the patients after genioplasty combined with BSSO.

The alternative to sliding genioplasty has been the insertion of a chin implant to augment soft-tissue volume without having to perform an osteotomy. According to Ward et al,³⁵ complication rates of this alternative are lower because of a decreased chance for nerve injury. Yaremchuk³⁶ reported that silicone implants in the midface are available to augment the malar region and the zygoma, and they have been clinically successful with low complications rates. One major issue related to silicone chin implants is bony resorption. Robinson and Shuken³⁷ reported that most patients show 3 to 5 mm resorption under the implant over time. This loss of bone tissue may lead to exposure of the roots of the incisor teeth. In 1983, Scaccia et al³⁸ surveyed more than 90 surgeons using silicone to perform more than 10,000 mentoplasty procedures and found an overall complication rate of 3%, including a 2% infection rate and an extrusion rate of 0.3%.

For the patients shown in Figures 1 and 2, the insertion of a chin implant or genioplasty may have also been a treatment option. However, both of these procedures are much more invasive and carry a higher risk of complications, including long-term risks such as implant displacement, foreign-body reaction, and exposure of the roots of the teeth.

In a recent survey, 100 South American oral and maxillofacial surgeons were asked whether they experienced specific complications in performing orthognathic surgery. The most common known complication was nerve damage after BSSO (91%), followed by condylar resorption (21%) and infection (9%).⁵ According to this group of surgeons,^{9,39,40}

infections after bimaxillary orthognathic surgery were reported in 2% to 33% of cases.

The Le Fort I osteotomy represents the standard procedure to correct midface hypoplasia and dental occlusion. Although Van de Perre et al⁴¹ reported a relatively low complication rate after orthognathic surgery procedures, asystole or severe bradycardia occurred during surgery in 2 of 2049 patients because of the trigeminovagal reflex. Other severe complications include a case series of 36 aseptic necroses of the maxilla,¹⁶ cranial nerve VI palsy,⁴² a combined damage of cranial nerves II, VI, V₁ and V₂,⁶ and blindness.¹⁵

With these complications in mind, most patients are requesting aesthetic corrections that carry a lower risk of potentially permanent damage. Del Vecchio and Rohrich⁴³ reported that over the past 10 years, soft-tissue augmentation by microfat grafting to address age-related tissue atrophy has become an effective method to achieve good aesthetic facial correction, leading to high patient satisfaction. This is underscored by the aesthetically pleasing results that were obtained in our own patient series (Figures 1-3 and Supplementary Figures 1-3). It is obvious that severe maxillary or mandibular hypoplasia with pronounced malocclusions, especially Type 3, require orthognathic correction. Proffit and White²⁴ found that malnutrition due to eating problems or restrictions of speech and breathing generally require surgical correction and cannot be corrected by orthodontic therapy alone. In our series, 113 patients (68%) exhibited a dental malocclusion, which was already treated or could be treated through orthodontic splinting.

In the opinion of many orthodontists,^{44,45} the limits of orthodontic treatment lie within an envelope of a positive overjet of 18 mm, a negative overjet of 4 mm, and a transverse width discrepancy of 3 mm. This extent of malalignment of the teeth, however, is not frequently encountered in clinical practice. It is highly unlikely that adult patients seeking the advice of a plastic surgeon to ameliorate the proportion and symmetry of their face will have major issues with their jaw, because this problem most likely would have been addressed at a much earlier age. These adult patients typically aspire to undergo a procedure with limited risks to improve their facial appearance. The mean follow-up period of 2 years and 7 months demonstrates durable results. Endara et al⁴⁶ found that fat grafting can also be applied as an adjunctive procedure to orthognathic and aesthetic skeletal surgery to obtain more precision and greater attainment of the intended aesthetic goals.

Weight gain after fat-grafting procedures may increase the volume of the grafted areas. However, fat growth after weight gain was not seen in our series. Based on our experience in facial rejuvenation surgery, overprojected areas after weight gain can easily be liposuctioned under local anesthesia.

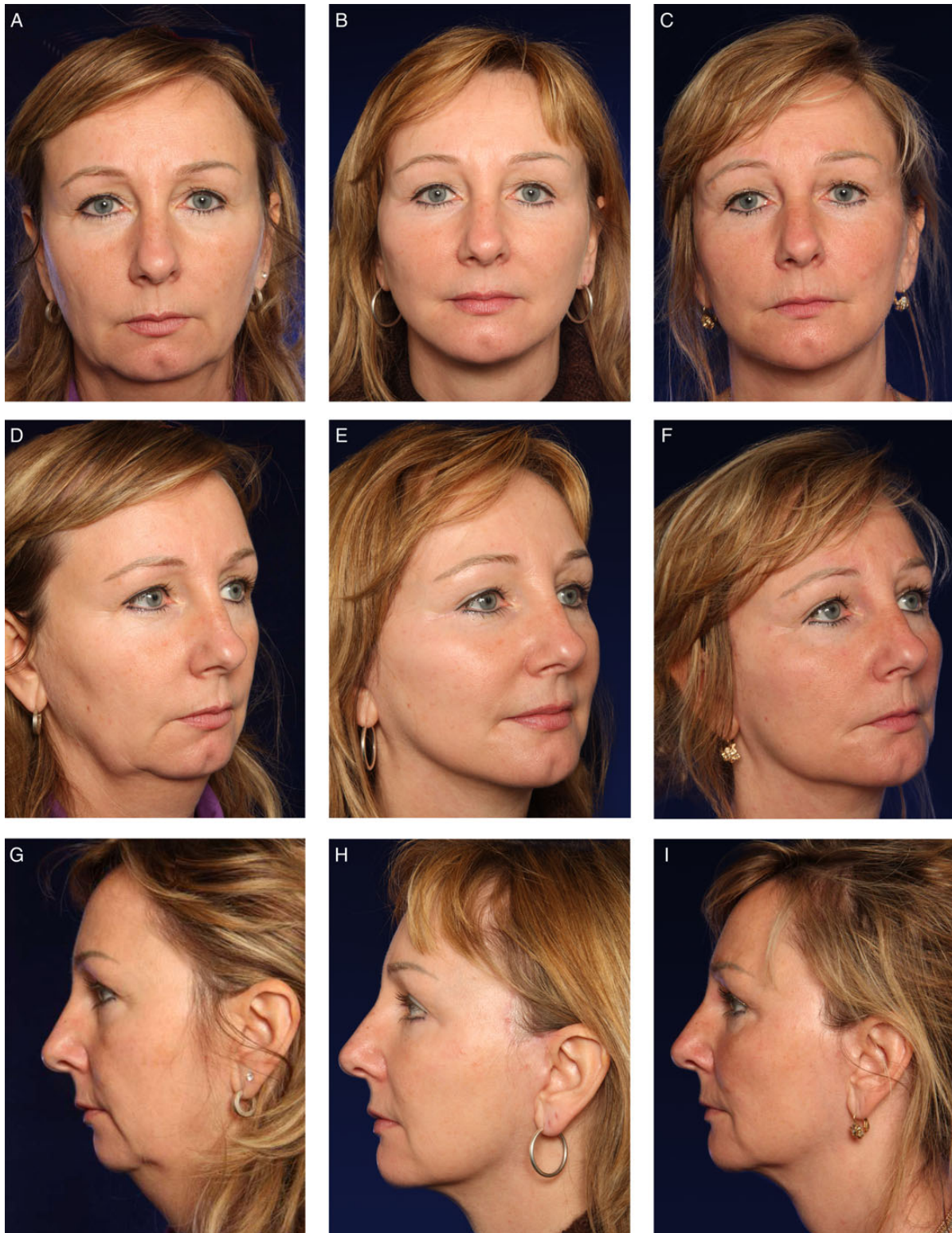

Figure 1. This 44-year-old woman consulted for facial rejuvenation. She presented with ptosis, blepharochalasis, and mild temporal hooding. (A, D, G) She also presented with facial disproportions due to moderate mandibular hypoplasia and retrusion of the chin. The patient underwent a combined minimal-access cranial suspension (MACS) lift, temporal lift, and lipofilling. The treated areas were the orbital malar area (right: 4 mL, left: 4 mL), the upper eyelid region (right: 0.8 mL, left: 1 mL), the nasolabial folds (right: 1.5 mL, left: 1.5 mL), the marionette grooves (right: 0.8 mL, left: 1 mL), and the chin (8 mL). The patient received 1 mL of sharp-needle intradermal fat grafting (SNIF) in the rhytids of the upper lip and 0.2 mL of SNIF in the corners of the mouth. Posttreatment photographs at 6 months (B, E, H) and 5 years (C, F, I) show the rejuvenation effect of the procedure and the stability of the volume change in the malar and chin areas.

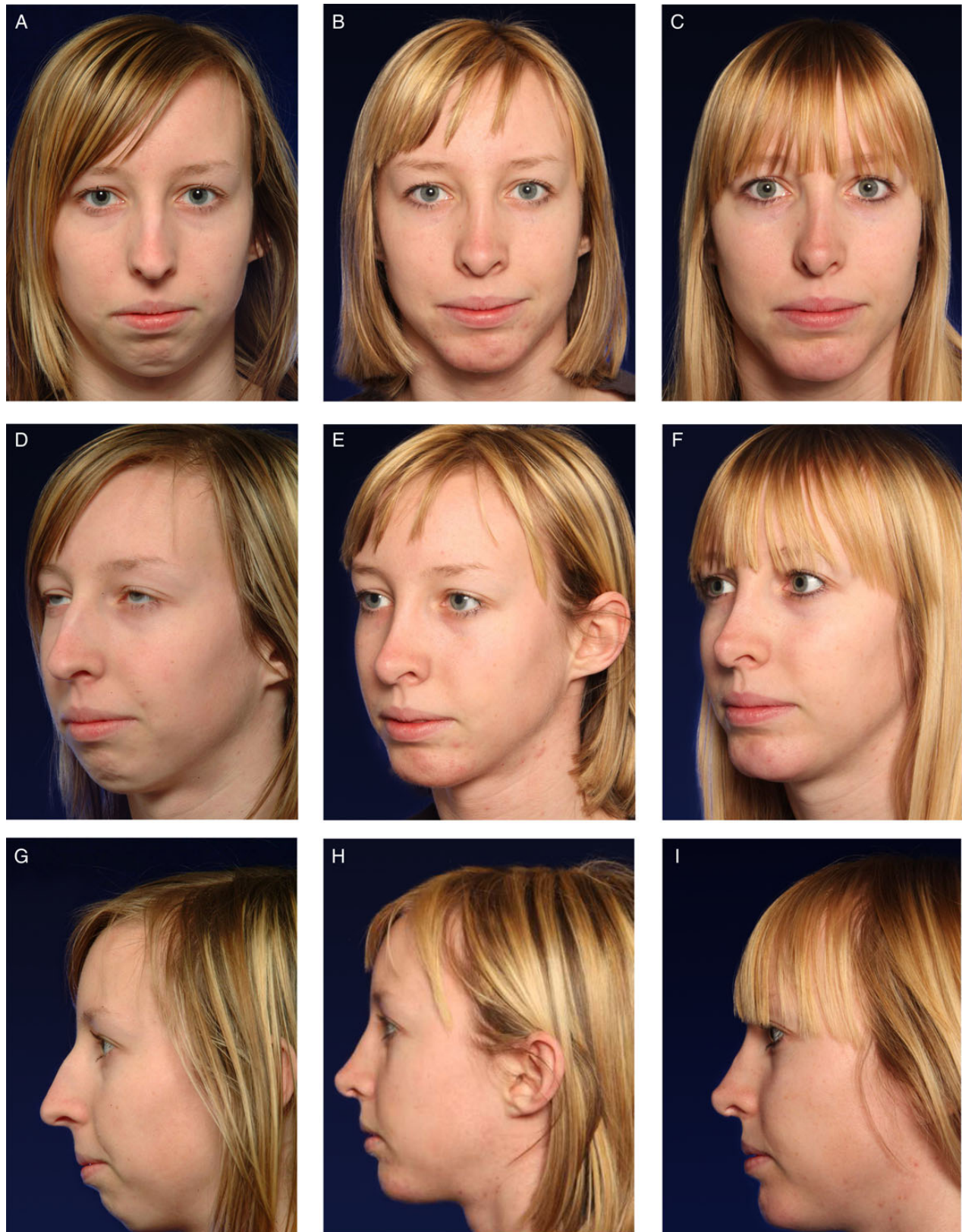


Figure 2. This 18-year-old woman consulted for facial contouring. (A, D, G) She presented with rhinokyphosis and hypoplasia of the chin with stable occlusion after orthodontic treatment. Therefore, 17 mL of microfat was grafted into the chin region. Nine months later the patient underwent a second procedure under local anesthesia in which 5 mL of microfat harvested from the abdomen was injected into the chin region. (B, E, H) The posttreatment result 11 months after the second infiltration shows the rhinoplasty result, which is a significant improvement in chin projection. (C, F, I) The photographs taken 5 years posttreatment prove the stability of the microfat grafting.

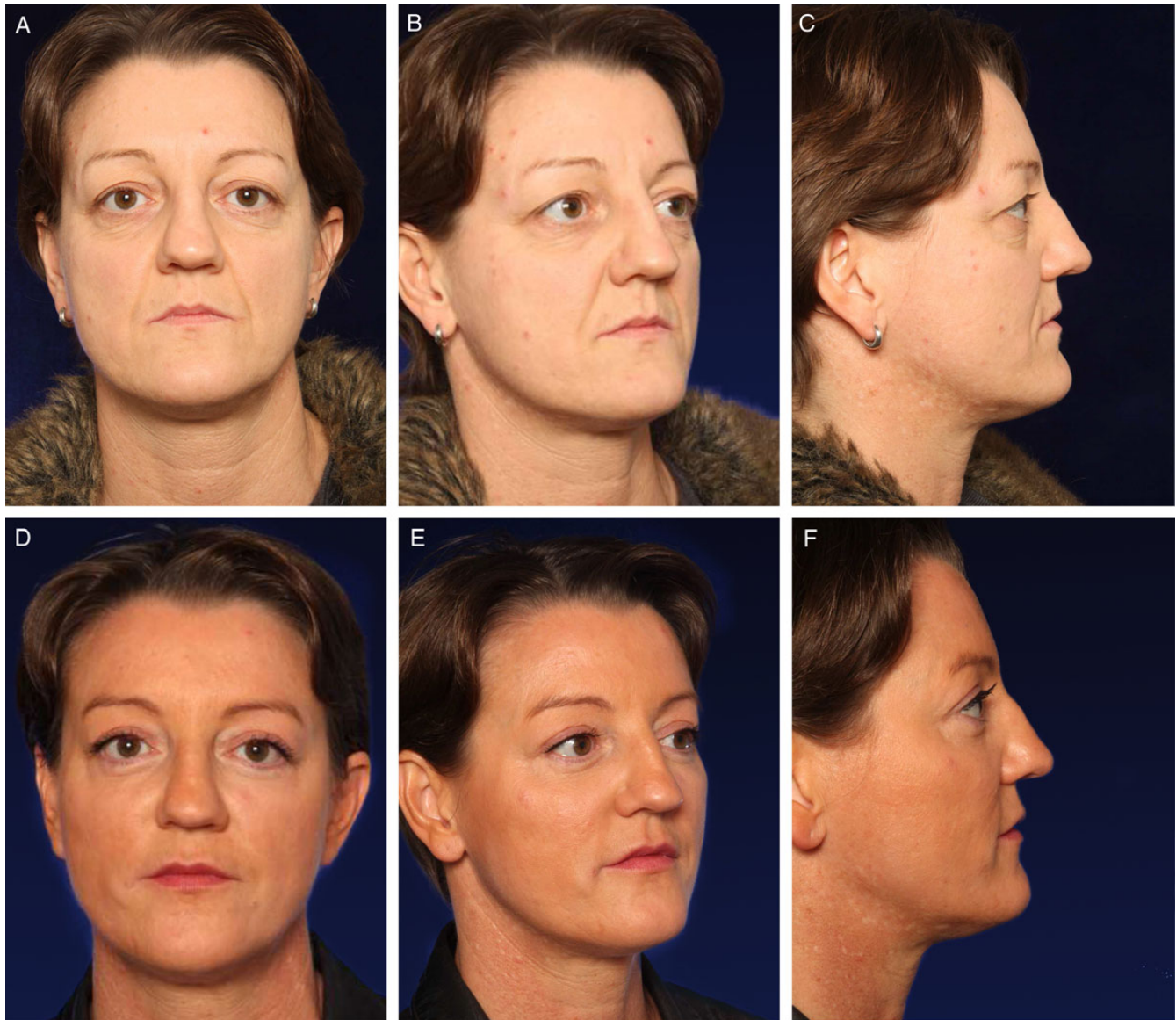

Figure 3. (A, B, C) This 41-year-old woman consulted for an upper and lower blepharoplasty. She also presented with moderate midfacial retrusion. An upper and lower blepharoplasty combined with lipfilling of the midface were proposed. The treatment was performed under local anesthesia. The upper blepharoplasty consisted of skin removal and an internal browpexy. The lower blepharoplasty consisted of limited skin removal and an orbicularis suspension. Microfat was grafted into the malar region (Right: 8 mL, left: 8 mL), the nasolabial folds (right: 1.6 mL, left: 1.7 mL), and the upper lip region (10 mL). In the upper lip, fat was distributed in the whole thickness of the lip—from the lip mucosa to the lip skin, from one nasolabial fold to the other, and from the nasal base to the vermilion—to augment the anterior projection of the lip region. The photographs taken 3 years after the procedure demonstrate the improvement of the anterior projection of the midface and the change of the proportion of the upper to lower lip projection because of the microfat grafting and show durable results (D, E, F).

Forty-three patients (26%) had a simultaneous rhinoplasty procedure during the facial fat augmentation procedure. It has been widely reported that patients with maxillary hypoplasia often complain about their nose, which they consider to be too large and conspicuous. This may actually be a visual impression that is mainly caused by the lack of volume in the area around the base of the

nose; that is, the malar area on both sides and the area below the philtrum and upper lip vermilion. It is conceivable that hypoplasia in this area will make the nose as the central facial structure appear bigger.

Limitations of our study are the fact that it is a retrospective, nonrandomized case series, which may lead to a potential selection bias. Patients were not compared to a

control group treated with orthognathic surgery alone or combined with facial implants. The evaluation of the results was performed clinically and based on patients' satisfaction, without any objective measurements (eg, surface scanner, MRI). Fat-resorption rate measurements were subjective.

CONCLUSION

It has been shown that improvement of facial symmetry and proportion has a significantly positive influence on patients' self-perception and satisfaction.⁴⁵ Facial microfat grafting is a safe and effective alternative to more complicated and potentially dangerous advancement osteotomies performed in patients for purely aesthetic reasons in the absence of any functional problems. The low morbidity and swift recovery associated with facial microfat grafting make it a valuable new tool in the armamentarium of the facial aesthetic surgeon.

Supplementary Material

This article contains supplementary material located online at www.aestheticsurgeryjournal.com.

Disclosures

The authors declared no conflicts of interest with respect to the research, authorship, and publication of this article.

Funding

The authors received no financial support for the research, authorship, and publication of this article.

REFERENCES

- Patel H, Thakkar C, Patel K. Parry-romberg syndrome: a rare entity. *J Maxillofac Oral Surg*. 2010;9(3):247-250.
- Chang CC, Steinbacher DM. Treacher collins syndrome. *Semin Plast Surg*. 2012;26(2):83-90.
- Hunstad JP, Shifrin DA, Kortesis BG. Successful treatment of Parry-Romberg syndrome with autologous fat grafting: 14-year follow-up and review. *Ann Plast Surg*. 2011;67(4):423-425.
- Nocini PF, Chiarini L, Bertossi D. Cosmetic procedures in orthognathic surgery. *J Oral Maxillofac Surg*. 2011;69(3):716-723.
- de Santana Santos T, Albuquerque KM, Santos ME, Laureano Filho JR. Survey on complications of orthognathic surgery among oral and maxillofacial surgeons. *J Craniofac Surg*. 2012;23(5):e423-e430.
- Kim JW, Chin BR, Park HS, et al. Cranial nerve injury after Le Fort I osteotomy. *Int J Oral Maxillofac Surg*. 2011;40(3):327-329.
- Gianni AB, D'Orto O, Biglioli F, et al. Neurosensory alterations of the inferior alveolar and mental nerve after genioplasty alone or associated with sagittal osteotomy of the mandibular ramus. *J Craniofac Surg*. 2002;30(5):295-303.
- Chow LK, Singh B, Chiu WK, Samman N. Prevalence of postoperative complications after orthognathic surgery: a 15-year review. *J Oral Maxillofac Surg*. 2007;65(5):984-992.
- Iannetti G, Fadda TM, Riccardi E, et al. Our experience in complications of orthognathic surgery: a retrospective study on 3236 patients. *Eur Rev Med Pharmacol Sci*. 2013;17(3):379-384.
- Kim SG, Park SS. Incidence of complications and problems related to orthognathic surgery. *J Oral Maxillofac Surg*. 2007;65(12):2438-2444.
- Mensink G, Zweers A, Wolterbeek R, et al. Neurosensory disturbances one year after bilateral sagittal split osteotomy of the mandibula performed with separators: a multi-centre prospective study. *J Craniofac Surg*. 2012;40(8):763-767.
- D'Agostino A, Trevisiol L, Gugole F, et al. Complications of orthognathic surgery: the inferior alveolar nerve. *J Craniofac Surg*. 2010;21(4):1189-1195.
- van Merkesteyn JP, Zweers A, Corputty JE. Neurosensory disturbances one year after bilateral sagittal split mandibular ramus osteotomy performed with separators. *J Craniofac Surg*. 2007;35(4-5):222-226.
- Pereira-Filho VA, Gabrielli MF, Gabrielli MA, et al. Incidence of maxillary sinusitis following Le Fort I osteotomy: clinical, radiographic, and endoscopic study. *J Oral Maxillofac Surg*. 2011;69(2):346-351.
- Cruz AA, dos Santos AC. Blindness after Le Fort I osteotomy: a possible complication associated with pterygo-maxillary separation. *J Craniofac Surg*. 2006;34(4):210-216.
- Lanigan DT. Injuries to the internal carotid artery following orthognathic surgery. *Int J Adult Orthodon Orthognath Surg*. 1988;3(4):215-220.
- Coleman SR, Saboeiro A, Sengelmann R. A comparison of lipoatrophy and aging: volume deficits in the face. *Aesthetic Plast Surg*. 2009;33(1):14-21.
- Zeltzer AA, Tonnard PL, Verpaele AM. Sharp-needle intradermal fat grafting (SNIF). *Aesthet Surg J*. 2012;32(5):554-561.
- Tonnard PL, Verpaele AM, Zeltzer AA. Augmentation blepharoplasty: a review of 500 consecutive patients. *Aesthet Surg J*. 2013;33(3):341-352.
- Gamboia GM, Ross WA. Autologous fat transfer in aesthetic facial recontouring. *Ann Plast Surg*. 2013;70(5):513-516.
- Kaufman MR, Bradley JP, Dickinson B, et al. Autologous fat transfer national consensus survey: trends in techniques for harvest, preparation, and application, and perception of short- and long-term results. *Plast Reconstr Surg*. 2007;119(1):323-331.
- Burnouf M, Buffet M, Schwarzingler M, et al. Evaluation of Coleman lipostructure for treatment of facial lipoatrophy in patients with human immunodeficiency virus and parameters associated with the efficiency of this technique. *Arch Dermatol*. 2005;141(10):1220-1224.

23. Giugliano C, Benitez S, Wisnia P, et al. Liposuction and lipoinjection treatment for congenital and acquired lipodystrophies in children. *Plast Reconstr Surg*. 2009;124(1):134-143.
24. Proffit WR, White RP Jr. Who needs surgical-orthodontic treatment? *Int J Adult Orthodon Orthognath Surg*. 1990;5(2):81-89.
25. Sarver DM, Weissman SM. Nonsurgical treatment of open bite in nongrowing patients. *Am J Orthod Dentofacial Orthop*. 1995;108(6):651-659.
26. Alexander RG, Sinclair PM, Goates LJ. Differential diagnosis and treatment planning for the adult nonsurgical orthodontic patient. *Am J Orthod*. 1986;89(2):95-112.
27. Harrison JE, Ashby D. Orthodontic treatment for posterior crossbites. *Cochrane Database Syst Rev*. 2000;(2):CD000979.
28. Harrison JE, O'Brien KD, Worthington HV. Orthodontic treatment for prominent upper front teeth in children. *Cochrane Database Syst Rev*. 2007;(3):CD003452.
29. Naragond A, Kenganal S, Sagarkar R, Sugaradday. Orthodontic camouflage treatment in an adult patient with a Class II, Division 1 malocclusion - a case report. *J Clin Diagn Res*. 2013;7(2):395-400.
30. Van Sickels JE, D'Addario M. Esthetic options with two jaw surgery. *Oral Maxillofac Surg Clin North Am*. 2007;19(3):423-433, vii.
31. Fattahi T. Aesthetic surgery to augment orthognathic surgery. *Oral Maxillofac Surg Clin North Am*. 2007;19(3):435-447, vii.
32. Patel PK, Novia MV. The surgical tools: the LeFort I, bilateral sagittal split osteotomy of the mandible, and the osseous genioplasty. *Clin Plast Surg*. 2007;34(3):447-475.
33. Pepersack WJ, Chausse JM. Long term follow-up of the sagittal splitting technique for correction of mandibular prognathism. *J Maxillofac Surg*. 1978;6(2):117-140.
34. Lindquist CC, Obeid G. Complications of genioplasty done alone or in combination with sagittal split-ramus osteotomy. *Oral Surg Oral Med Oral Pathol*. 1988;66(1):13-16.
35. Ward JL, Garri JI, Wolfe SA. The osseous genioplasty. *Clin Plast Surg*. 2007;34(3):485-500.
36. Yaremchuk MJ. Making concave faces convex. *Aesthetic Plast Surg*. 2005;29(3):141-147; discussion 148.
37. Robinson M. Bone resorption under plastic chin implants. Follow-up of a preliminary report. *Arch Otolaryngol*. 1972;95(1):30-32.
38. Scaddia FJ, Allphin AL, Stepnick DW. Complications of augmentation mentoplasty: A review of 11095 cases. *Int J Aesthetic Restorative Surg*. 1993;1:3-8.
39. Bentley KC, Head TW, Aiello GA. Antibiotic prophylaxis in orthognathic surgery: a 1-day versus 5-day regimen. *J Oral Maxillofac Surg*. 1999;57(3):226-230; discussion 230-232.
40. Zijderveld SA, Smeele LE, Kostense PJ, Tuinzing DB. Preoperative antibiotic prophylaxis in orthognathic surgery: a randomized, double-blind, and placebo-controlled clinical study. *J Oral Maxillofac Surg*. 1999;57(12):1403-1406; discussion 1406-1407.
41. Van de Perre JP, Stoelinga PJ, Blijdorp PA, et al. Perioperative morbidity in maxillofacial orthopaedic surgery: a retrospective study. *J Craniomaxillofac Surg*. 1996;24(5):263-270.
42. Hanu-Cernat LM, Hall T. Late onset of abducens palsy after Le Fort I maxillary osteotomy. *Br J Oral Maxillofac Surg*. 2009;47(5):414-416.
43. Del Vecchio D, Rohrich RJ. A classification of clinical fat grafting: different problems, different solutions. *Plast Reconstr Surg*. 2012;130(3):511-522.
44. Squire D, Best AM, Lindauer SJ, Laskin DM. Determining the limits of orthodontic treatment of overbite, overjet, and transverse width discrepancy: a pilot study. *Am J Orthod Dentofacial Orthop*. 2006;129(6):804-808.
45. Rustemeyer J, Eke Z, Bremerich A. Perception of improvement after orthognathic surgery: the important variables affecting patient satisfaction. *Oral Maxillofac Surg*. 2010;14(3):155-162.
46. Endara MR, Allred LJ, Han KD, Baker SB. Applications of fat grafting in facial aesthetic skeletal surgery. *Aesthet Surg J*. 2014;34(3):363-373.