

HYPERENHANCEMENT PATTERNS

Ischemic

A. Subendocardial Infarct



B. Transmural Infarct



Nonischemic

A. Mid-wall HE

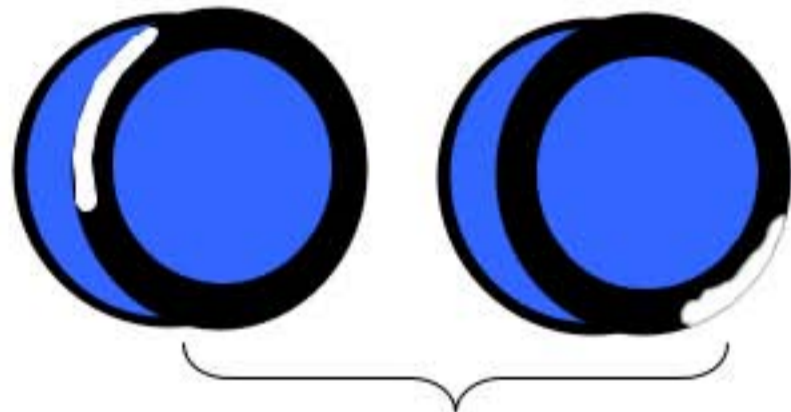


- Idiopathic Dilated Cardiomyopathy
- Myocarditis

- Hypertrophic Cardiomyopathy
- Right ventricular pressure overload (e.g. congenital heart disease, pulmonary HTN)

- Sarcoidosis
- Myocarditis
- Anderson-Fabry
- Chagas Disease

B. Epicardial HE



- Sarcoidosis, Myocarditis, Anderson-Fabry, Chagas Disease

C. Global Endocardial HE



- Amyloidosis, Systemic Sclerosis, Post cardiac transplantation

Figure 13